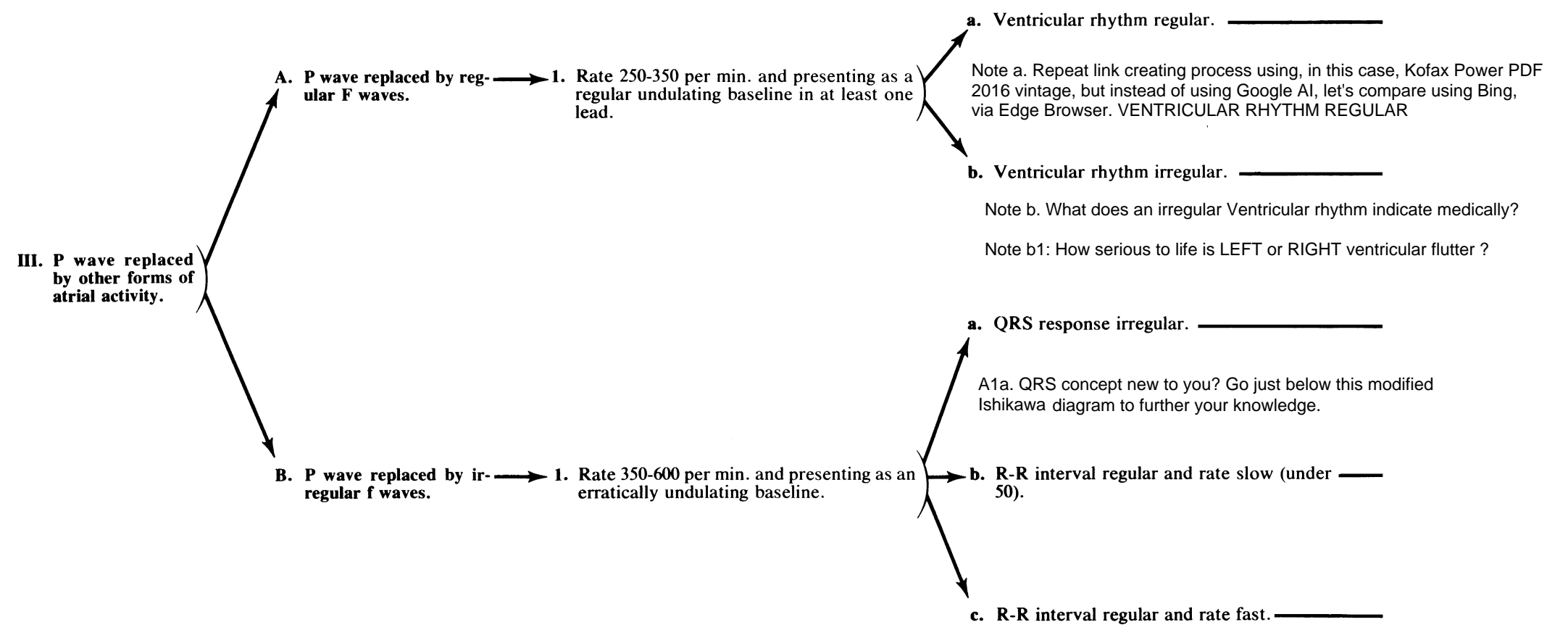
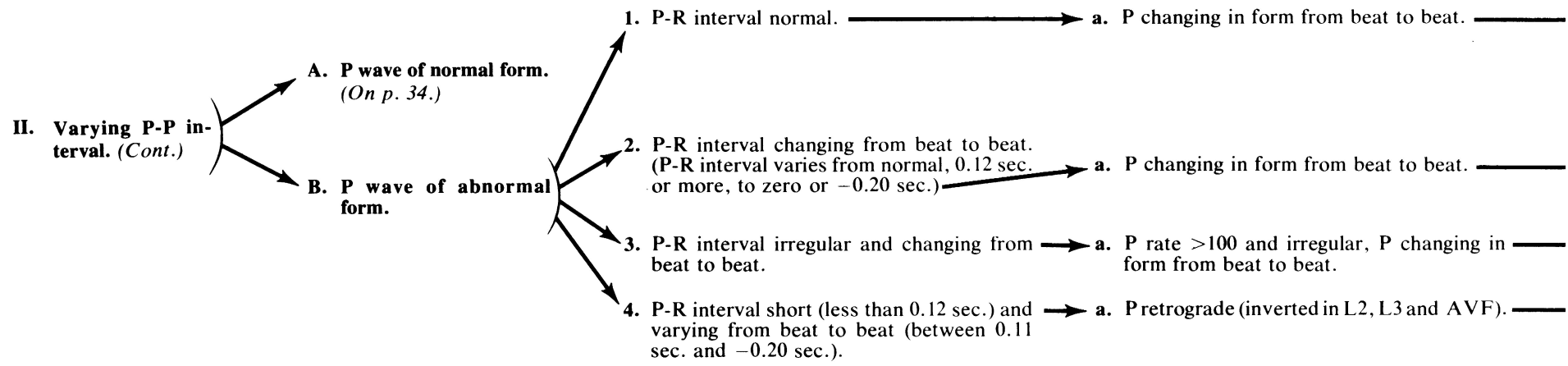


ARRHYTHMIAS—DIAGNOSES BASED ON THE P WAVE OR OTHER ATRIAL ACTIVITY (Cont.)



QRS, the BASICS FIRST. Introduction to EKG Interpretation, Waveforms, Segments, Intervals by Strong Medicine 10 min. video tutorial

36

How to read an EKG (Made Easy - - - sort of. Nothing worth learning is ever easy. What is easy is quitting when the going gets tough. But your secret to success is in this word: perseverance.